

Article

Study on the role of albendazole in physiological and histological changes in farm chicken infected with environmental parasites in Dawmat AlJandal, AlJouf, Saudia Arabia Kingdom

Hanan T. Hamza^{*1,2}, Aziza J.T. Al-Namasi¹, Fanar R.R. Al-Ruwaili¹, Hoda S.M. Al-Shammari¹, Ibrahim Aly^{*3}.

¹Biology Department, College of Science, Jouf University, Sakaka 2014, Saudi Arabia

²Department of Zoology, Faculty of Science (Girls), Al-Azhar University, Yousef Abbas Str., Nasr City, Cairo, Egypt.

³Parasitology Department, Theodor Bilharz Research Institute, Cairo, Egypt.

*Correspondence: httaher@ju.edu.sa

Received: 01-05-2024, Revised: 30-05-2024, Accepted: 10-06-2024 e-Published: 12-06-2024.

Abstract:

Background: Farm birds, or chickens, are susceptible to a variety of parasite infections that are spread by people. The anti-parasitic medication of choice is albendazole (ABZ). This article's main objective is to examine the effects of ABZ on the intestine and hepatic tissue of farm hens. **Methods:** ABZ recorded an egg reduction rate (ERR) of almost 100% and a cure rate (CR) of 96% (egg negative conversion rate, or NCR) with 400 mg given all at once. A total of 20 farm chickens were divided into 4 groups (5 chickens/ group): (G1) non-infected, untreated group, (G2) infected, untreated group, (G3) is non-infected ABZ-treated group, and (G4) is infected ABZ-treated group. **Results:** Regarding the average number of worms (*Ascaris*) (G2) and (G4) recovered from the gut increased significantly ($P<0.01$). While there was a significant decrease in the average number of worms (G4) (25%) compared to those infected only (48%). The results obtained also showed a highly significant increase ($P<0.05$) in the average number of worms in the intestines among the infected group. (Hymenolipes) (G2) (41%), while there was a significant decrease in the average number of worms (G4) (17.3%) compared to those infected only. AST levels showed a significant increase in groups (G2) and (G4) compared to the normal control group. The percentage increase reached 124.65% and 256.33%, respectively at $P<0.001$ and $P<0.01$. While (G3) treated with albendazole recorded a decrease rate of 51.85%. AST levels in the plasma of groups (G3) and (G4) recorded a significant increase compared to the infected control group (G2). An increase in ALT was recorded in groups (G2) compared to the control group (G1). The percentage increase reached 127%. An increase in ALT was recorded in groups (G2) and (G4) compared to the normal group (G1). The percentage increase reached 127% and 48.03%, respectively. The histological study of both the liver and intestines demonstrated the pathological effect of the tissues treated with albendazole, and on the contrary, the treatment affected the decrease in the number of worms in the intestines. **Conclusions:** The study

indicates that treatment with albendazole for chickens infected with various parasites led to a decrease in the number of worms. It also led to an increase in the values of liver enzymes and also some abnormalities in both the liver and intestines.

Keywords: Albendazole; liver enzymes; pathological effect; cure rate; egg reduction rate; intestinal tissue; liver toxicity; drug resistance.

1. Introduction

Diseases, such as toxoplasmosis, liver worm disease, tapeworm, and others, are among the common illnesses whose significance in livestock health and public health cannot be overlooked. These conditions harm the opportunity for livestock development and increase the efficacy of its products [1]. Protozoan infections include giardiasis, vaginal trichomoniasis, cryptosporidiosis, and microsporidiosis; trematode infections, on the other hand, include fascioliasis, clonorchiasis, opisthorchiasis, and intestinal strike infections, have all been treated with albendazole. Generally speaking, these medications are safe with a wide range of adverse effects; nevertheless, if taken more than once or for an extended period (more than 14–28 days). Once, liver toxicity and other adverse reactions, along with liver damage and other side effects, may develop. There are growing concerns about drug resistance in hookworms, *Trichuris trichiura*, maybe *Ascaris lumbricoides*, *Wuchereria bancrofti*, and *Giardia sp.* Notably, mebendazole and albendazole have been sidelined as potentially effective anti-cancer medications. These medications are effective against carcinoma, colorectal, liver, lung, ovarian, prostate, bone, and head and neck cancers both in vitro and in vivo (in animals). Two case reports for mebendazole and two clinical reports for albendazole have shown the potential benefits of these medications in fatal instances involving a variety of cancer types. Mebendazole is currently more frequently utilized than albendazole in anti-cancer clinical trials due to the toxicity of albendazole, which can produce side effects such as neutropenia from myelosuppression if large dosages are taken for an extended period of time [2].

However, mebendazole is currently more frequently utilized than albendazole in anti-cancer clinical trials due to the toxicity of albendazole, such as neutropenia brought on by myelosuppression if large doses are taken for an extended period. To address zoonoses and other common health hazards that affect people, animals, and the environment, cooperation between all sectors and disciplines responsible for health is required, according to a WHO report [3]. Health issues at the interface between humans, animals, and the terrain cannot be effectively addressed in one sector alone. Reactive oxygen species (ROS) are produced during both metabolic processes and the biotransformation of xenobiotics, and the liver is an organ that is particularly vulnerable to them. Redox balance disruption leads to oxidative stress, which alters seditious pathways, impairs liver function, and increases symptoms. Thus, oxidative stress plays a role in the etiology of metabolically-driven chronic liver disorders as well as acute liver injury [4]. This brief study addresses the usage of mebendazole and albendazole, sometimes referred to as broad-diapason anthelmintics (benzimidazole) in the treatment of parasitic diseases and cancer. By obstructing the microtubule networks in human and sponge cells, these drugs can reduce the absorption and transportation of glucose and ultimately result in cell death. Ultimately, these compounds exert tumoricidal effects on hosts and larvicidal, vermicial, and ovicidal effects on parasites. Albendazole and mebendazole are commonly given to treat intestinal nematode infections, which include ascariasis, hookworm infections, trichuriasis, strongyloidiasis, and enterobiasis. However, they can

also be used to treat intestinal tapeworm infections, which include hymenolepiasis and taeniasis. However, these drugs also demonstrate potential in treating diseases brought on by towel nematodes and cestodes (visceral, ophthalmic, neurologic, and cutaneous naiad migrans, anisakiasis, trichinosis, and hepatic capillaries and intestines).

EL-Sheikh et al. [5] calculated how albendazole affected the histopathological alterations in broiler chickens as well as renal and liver function. In the chicken liver under histopathological examination, there were prominent interstitial round cell aggregations together with dilated blood vessels (PBV), portal round cell aggregation (RCA), and biliary proliferative hyperplasia (BP). Chickens given albendazole showed signs of both hepatocellular degeneration (HCD) and individual cellular apoptosis (HCA). The impact of beneficial variables and other potential limitations on the size, growth, and function of the liver are not well documented, despite the enormous liabilities associated with avian species. This makes consideration of the variables that may affect and change liver function aspects of liver structure and function extremely pertinent [6]. By preventing the microtubules from tubulin from conforming properly, albendazole interferes with the survival and reduplication of helminths, or roundworms. This causes the cell to die by impairing its ability to absorb glucose and reducing its stores of glycogen. The sulfoxide outgrowth of albendazole is produced in the liver of the bird during its metabolism. Albendazole sulfoxide has high levels of plasma, rendering it efficacious against both adult and young worms present in the gastrointestinal tract as well as in different host tissues and organs extraintestinal. Poultry suffering from liver diseases or abnormalities should not be given albendazole. The drug's quick metabolism in the liver accounts for this. Each bird has to be administered albendazole orally by hype into its mouth. Albendazole's water solubility is insufficient, as is the case with all benzimidazoles [7].

2. Materials and Methods

2.1. Sampling of animals

During the duration of the study, a routine stool examination was performed to describe the color and consistency of the chickens' intestine samples. Microscopy aided in the detection of ova, cysts, trophozoites, larvae or worms of the different intestinal parasites. Positive results were obtained from the bird groups, and laboratory reports were recorded and tabulated. Frequency, mean, and percentage were used to analyze the data statistically.

2.2. Experimental animal groups and design

This study was conducted on 20 chickens from a private farm in Dawmat AlJandal, regardless the weight of the chicken. Chickens were classified into 4 experimental groups (5 chickens/ group):

Group I (G1): Sacrificed as negative control group (non-infected, untreated), Group II (G2): Sacrificed as positive control group (infected, untreated), Group III (G3): Sacrificed as a non-infected group but treated with albendazole, and Group IV (G4): Sacrificed as infected group treated with albendazole.

2.2.1. Dosage of Albendazole

The earliest clinical study in 1982 used ABZ in a single oral dose of 400 mg. This dose was reported to result in 96% CR (=egg negative conversion rate (NCR)), and 100% ERR [8]. Chai & Hong, Keiser & Utzinger, Soukhathammavong et al, and Moser et al. [9-12] recorded CR percentage (81-100%) and ERR percentage (87-100%) for Ascariasis. While they recorded CR (72-96%) and ERR (64-100%)

for hook worms. The same dose was used for trichuriasis, strongyloidiasis, and enterobiasis and different CR and ERR percentages were recorded [9-13].

2.2.2. The 4 groups were suspected to the following

At the end of each experiment, blood samples were collected directly from the heart of the anesthetized animals followed by plasma separation, and then stored at 4 °C until used. These plasma samples were subjected for liver function tests; alanine aminotransferase (ALT) and aspartate aminotransferase (AST) using Spectrum-Diagnostics Kits (Biodiagnostic), and following the manufacturer's method. The liver and intestine tissues of all dissected animals were processed for histopathological preparation and stained by hematoxylin and eosin according to [14].

2.3. Intestinal worm load

The intestine was opened, washed, and then left in saline for 2 h to allow worms to exit. Washing was carried out several times till the fluid became clear. Then, the collected fluid was centrifuged at 1500 rpm for 5 min to obtain sediment containing the worms. Worms were counted using a dissecting microscope [15].

2.4. Statistical analyses

Statistical analysis was performed using analyses of variance (ANOVA). Significant differences between treatment means were determined by the student *t-test*. Data were presented as mean \pm SE and, the difference was statistically significant at $P \leq 0.05$.

3. Results

3.1. Parasitological measures

3.1.1. Intestinal worm load

The results obtained in the current study showed a significant increase ($P < 0.05$) in the percentage of worms in G2 (the infected untreated group) and G4 (infected group treated with ABZ). The percentage of increase in the total number of *Ascaris* worms was 70%. While a significant reduction ($P < 0.05$) in the load of *Hymenolepis nana* (*H. nana*) worm and *Entamoeba histolytica* (*E. histolytica*) by 30% was observed (Figs. 1, 2 and Table 1).




Figure 1. Showing trophozoites of *E. histolytica* from the stool of chickens (G2) infected, and untreated group.

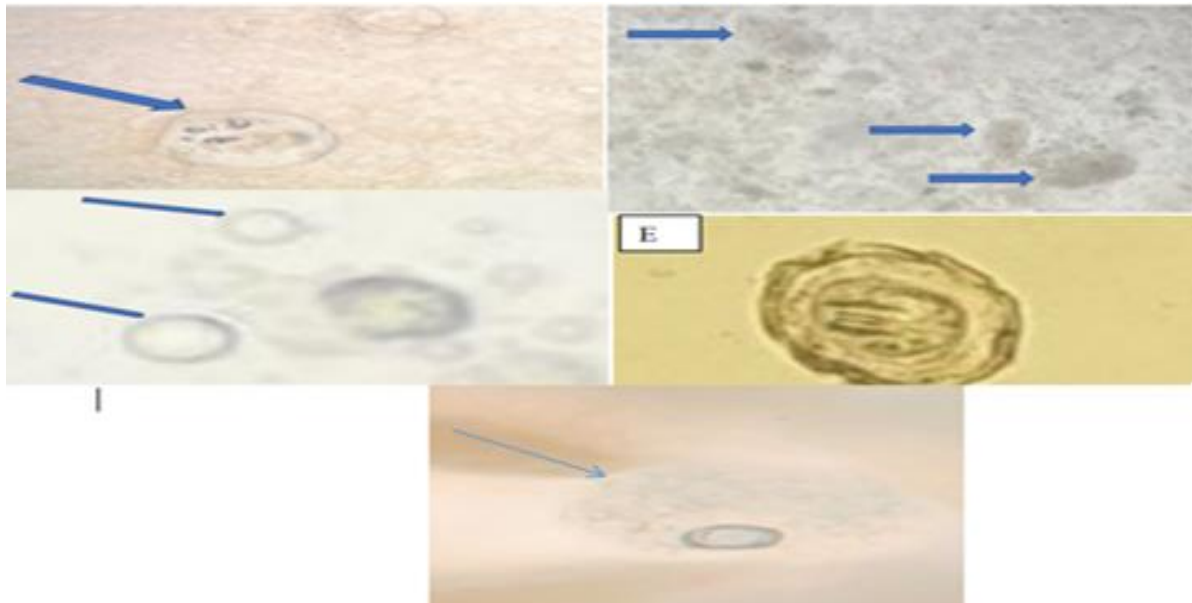


Figure 2. Showing different photos of different cysts and trophozoites of *E. histolytica* (E), and eggs of *H. nana*.

The present study showed that *H. nana* is prevalent in some localities in Al-Jouf at a significant level. Farm factors such as breed, clinical signs, and movement pose a great risk of in Dawmat AlJandal chicken breeding sites. A more longitudinal study would be useful to better understand the incidence dynamics according to herd factors.

Table 1. Parasitic zoonosis prevalence in the livestock of Dawmat AlJandal province at AlJouf region.

Parasitic zoonosis	Study area	Species	Prevalence (%)	Method
*Nematoda	Dawmat AlJandal	Chicken	70%	Intestinal samples Wet mount
<i>Ascaris</i> sp.				
<i>Enterobius vermicularis</i>				
*Protozoal diseases				
<i>E. histolytica</i>	30%	Concentration techniques		
*Cestoda				
<i>H. nana</i>				

E. histolytica is not easily transmitted from animals to humans, because this parasite rarely encysts in the intestinal lumen of animals which is an important factor in the transmission of this parasite.

Regarding to mean number of worms recovered from intestines, the results obtained showed a highly significant ($P<0.01$) increase in the mean number of the *Ascaris* worm counts in G2 group when compared to G1 and G3 groups. Meanwhile, significant ($P<0.01$) increase in the mean number of all worms in G4 group when compared to G1 and G3 groups. Whilst there was a significant

($P<0.01$) reduction in the mean number of *E. histolytica* and *H. nana* worm counts in G4 (25%) when compared to G2 (48%). Also, the results obtained showed a highly significant ($P<0.05$) increase in the mean number of *Hymenolipes* worm count intestines between the infected group (G2, 41%). While there was a significant reduction in the mean number of worms count in G4 group (17.3%) when compared to infected only G2 group (Fig. 3 and Table 2).

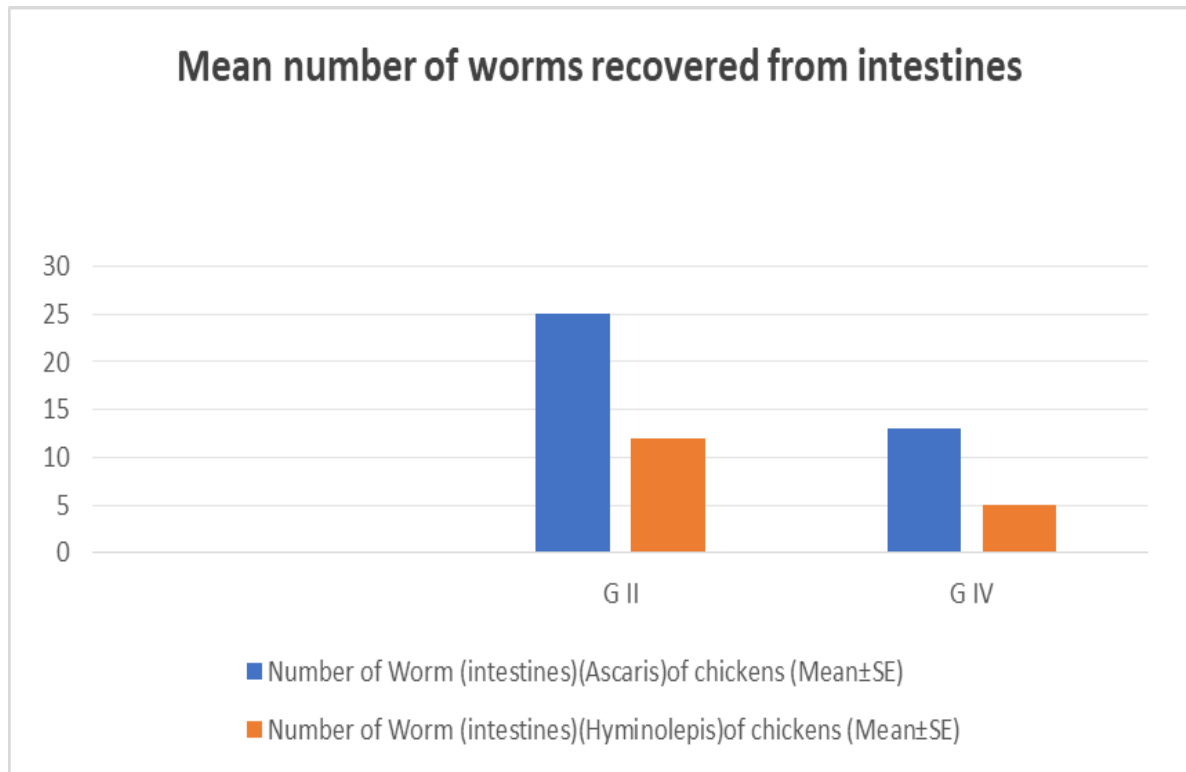


Figure 3. Showing differences between groups infected (G2) and infected and treated with ABZ (G4) in the mean number of worms recovered from intestines.

Table 2. Mean number of worms recovered from intestines.

Groups	Number of <i>Ascaris</i> worm in chickens (Mean±SE)	Number of <i>Hymenolipes</i> worm in chickens (Mean±SE).
G2	25±18.9*, 48% increase	12 ±1.08*, 41.6% increase
G4	13±9.7*, 25% reduction	5 ±1.08*, 17.3% reduction

(*) Significantly different from each infected group at $P<0.01$.

Tapeworms such as dwarf worms, which are transmitted to humans by food and drink contaminated with worm eggs or larvae, informed us the presence of external parasites such as ticks or lice, which are transmitted to humans through the bite of an infected tick or lice with any other parasitic diseases. It is worth noting that we could not obtain specific numbers, either for the parasites themselves or for the animals infected with this branch (Figs. 4-6).



Figure 4. Showing worms of *Hymenolepis* recovered from the intestines of chickens infected and treated with ABZ (G4). (A): Adult stage.




Figure 5. Showing worms of *Ascaris* recovered from the intestines of chickens (G2 & G4).




Figure 6. Showing worms of *Hymenolepis* recovered from the intestines of chickens (G2). (L): Larval stage.

3. 2. Biochemical analysis among infected and treated groups of birds

3.2.1. Aspartate aminotransferase activity (AST)

The levels of AST showed a significant increase in groups G2, and G4 when compared to the negative control group (G1). The percentage of increase was 124.65% and 256.33%, respectively. While G3 (treated with ABZ) recorded the percentage of decrease of 51.85%. Also, levels of AST in groups G2, and G4 showed a highly significant increase when compared to the group G3. Furthermore, the levels of AST in the plasma of groups G3 and G4 recorded a significant increase when compared to the infected control group (G2) at $P<0.001$ and $P< 0.01$ (Fig. 7 and Table 3).

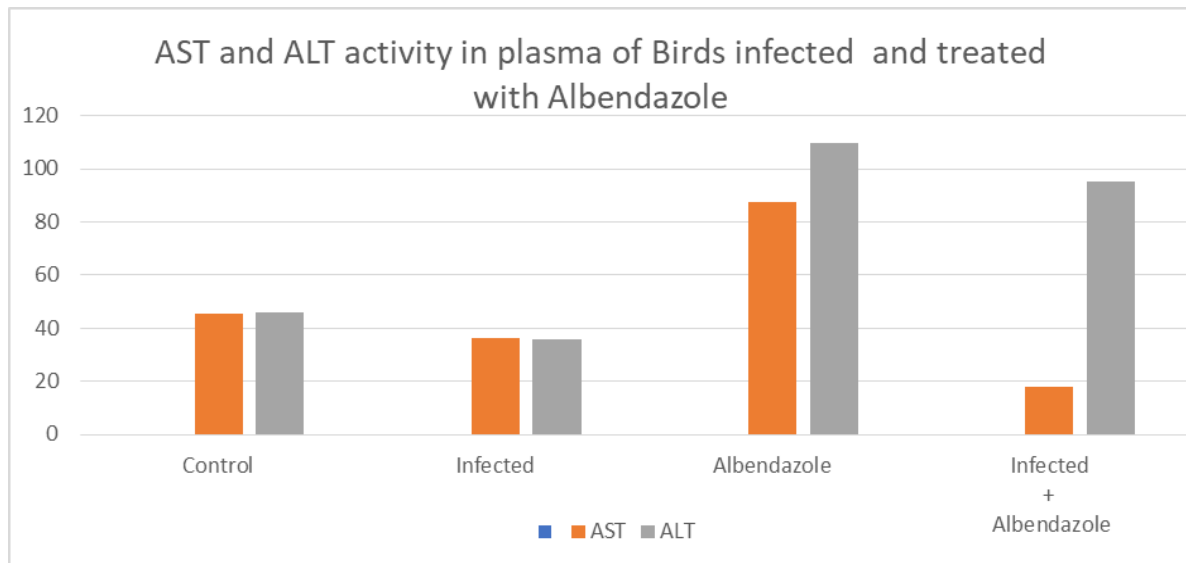


Figure 7. Showing the difference between AST and ALT activity in the plasma of chickens infected and treated with ABZ (G4).

3.2.2. Alanine aminotransferase activity (ALT)

The increase of ALT was recorded in groups (G2) and (G4) when compared to the negative control group (G1). The percentage of increase was 127% and 48.03%, respectively. While G3 group, treated with ABZ recorded the percentage of decrease of 41.68%. Also, levels of AST in groups G2, and G4 showed a highly significant when compared to G3 group. The levels of ALT in the plasma of groups (G3) and (G4) recorded a significant increase when compared to the positive control group (G2) at $P<0.001$ and $P< 0.01$ (Fig. 7 and Table 3).

Table 3. AST and ALT activity in plasma of chickens infected and treated with ABZ (G4).

Groups	G1	G2	G3	G4
AST	45.5 ± 2.65	36.5 ± 14.36*~	87.75 ± 0.14***^^^	77.75 ± 3.86***^^~
%Difference		124.65%	51.85%	256.33%
Significance		$P<0.05$	$P<0.001$	$P<0.001$
ALT	45.75 ± 4.31	36 ± 1.34*~	109.75 ± 4.33***^^^	95.25 ± 16.17***^^~
%Difference		127.00%	41.68%	48.03%
Significance		$P<0.05$	$P<0.001$	$P<0.01$

Significantly different from G1 group: *at $P<0.05$, **at $P<0.01$, ***at $P<0.001$.

Significantly different from G2 group: ^at $P<0.05$, ^^at $P<0.01$,^^^at $P<0.001$.

Significantly different from G3 group: ~at $P<0.05$, ~~at $P<0.01$, ~~~at $P<0.001$.

3.3. Histopathological results

3.3.1. Intestinal Study

In the infected untreated group (G2), the microscopic examination showed the presence of eggs in the lumen of intestinal villi as well as degenerated and desquamated mucosa associated with excessive mucin in the intestinal lumina. Some inflammatory cells were accumulated in the villi lumina. Some villi lost their normal architecture with cells exhibiting degenerated cytoplasmic organoid that surrounds pyknotic nuclei (Fig. 8). While among ABZ-treated group (G3) most of the sections showed normal appearance of the intestinal structure, but others showed incomplete healing, numerous vacuolated cells, numerous pyknotic nuclei, and numerous degenerated areas (Fig. 8). In group G4 (infected-ABZ-treated group), some intestinal sections showed normal appearance of the intestinal lumen and villi. Some other sections showed degenerated muscle fibers, ruptured mucosal layer of the villi, and degenerated cytoplasmic organoid which surrounds pyknotic nuclei (Fig. 8). In group G4, sections of the intestine showed the presence of *H. nana* remnant, highly dividing cells, and increased proliferation in the submucosa. While intestinal sections in the group G2 showed normal appearance, some of them showed cells with poorly stained degenerated cytoplasmic organoids that surround pyknotic nuclei (Fig. 8).

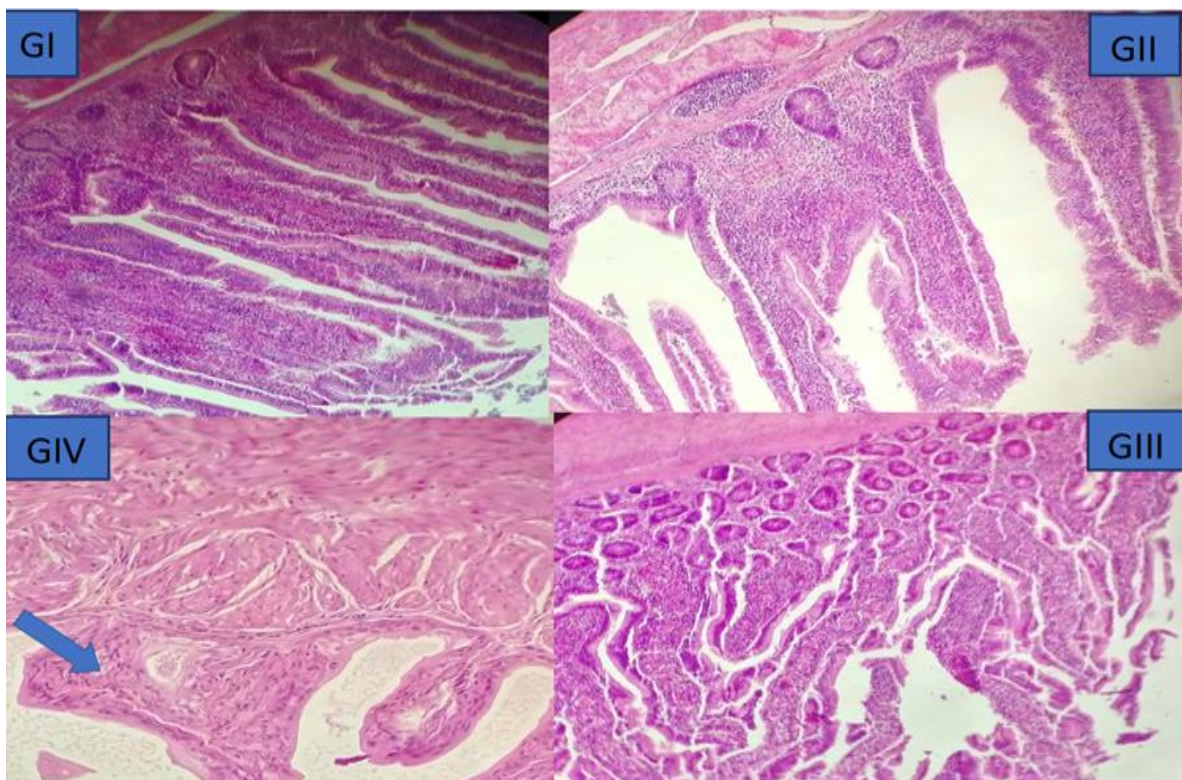


Figure 8. Photomicrograph of the small intestine of normal chicken showing the presence of *H. nana* remnant (arrow), highly dividing cells, and increased proliferation in the submucosa (G1). While infected chicken (G2) showing the normal appearance of the intestinal structure, incomplete healing, numerous vacuolated cells, numerous pyknotic nuclei (thick arrow), and numerous degenerated areas. On the other hand, infected-ABZ-treated showing faintly stained degenerated cytoplasmic organoids that surrounded pyknotic nuclei (G4) (thick arrow). While chickens ABZ-treated showing highly aggregated inflammatory cells (curved arrow) (G3). Sections are H & E-stained, X= 200, 400.

3.3.2. Hepatic Study

In the infected untreated group (G2), the microscopic examination showed the presence of inflammatory cell accumulation around the central vein, hepatic artery, bile duct, and hepatic sinusoidal tissue. Most of the hepatocytes represented a spongy structure and others lost their nuclei. While ABZ-treated group (G3) revealed highly dilated sinusoidal space. Also, accumulated inflammatory cells around the hepatic and portal veins were found. Normal hepatocytes and activation of Kupffer cells were also seen. In group (G2), liver sections showed normal appearance of liver tissue associated with dilation and congestion of portal vein (Fig. 9). In infected and treated group (G4), liver sections showed the presence of hydropic degeneration, apoptotic cells, inflammatory cells accumulation, and congested central vein and hepatic portal blood vessels with completely hemolyzed RBCs. While in the treated only group (G3) liver sections showed many hepatocytes represented hydropic degeneration and inflammatory cell accumulation. Hepatic portal vein showed signs of RBCs hydrolysis. Also showed vacuolated hepatocytes (hydropic degeneration), apoptotic cells, inflammatory cells accumulation, and widening of the blood vessel with the presence of others containing completely hemolyzed blood cells (Fig. 9).

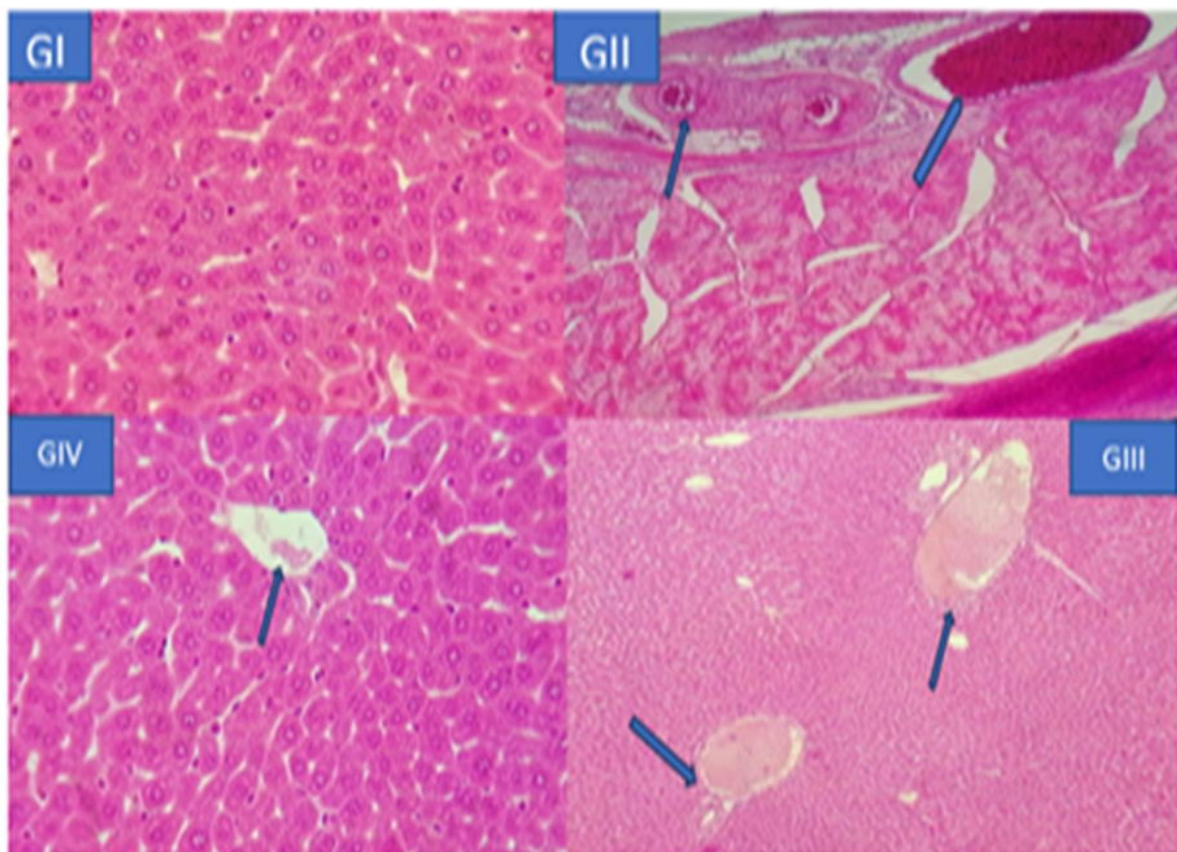


Figure 9. Photomicrograph of the liver (G1 & G4) showing normal histological characterization of different structures, (G2) showing Liver lipid content, dilated blood vessel (PBV), portal round cells aggregation (RCA), and biliary proliferative hyperplasia (BP), marked interstitial round cells aggregations, hepatocellular degeneration (HCD) and individual cellular apoptosis, while (G3) showing many hepatocytes representing hydropic degeneration and inflammatory cell accumulation. Hepatic portal vein (HPV) showing signs of RBCs hemolysis. Also, (G4) shows dilated blood vessels (PBV). Sections are H & E-stained, X= 100,400.

4. Discussion

Similar to mammals, the liver of birds performs a variety of metabolic and homeostatic tasks. It is regarded as a biochemical factory that handles the majority of the activities involved in digestion, metabolism, excretion, and detoxification. It is crucial to digestion and metabolism because it controls the synthesis, storage, and release of proteins, fats, and carbs. Blood proteins, enzymes, hormones, coagulation factors, and immunological factors are just a few of the proteins that the liver produces. It is both an exocrine and an endocrine gland. This organ needs to be maintained in top shape to keep a bird healthy. The production of healthy birds depends on a deeper comprehension of metabolic processes and variables that can result in liver problems [6]. For both adult and larval stages of *Ascaridia galli*, *Heterakis gallinarum*, and *Capillaria obsignata*, Tucker et al. [16] reported statistically significant reductions in worm burdens from control values at the 5.0 mg/kg treatment level. Only after treating at a dose of 20.0 mg/kg did the number of *Raillietina cesticillus* (scolexes) significantly decrease from levels observed in the control group. Based on geometric means, the separate anthelmintic efficaciousness for ABZ administered at dosages of 5.0, 10.0, and 20.0 mg/kg was 87.7, 91.2, and 98.2% for *A. galli* larvae; 100, 100, and 100% for *A. galli* adults; and 96.9, 95.7, and 98.9% for *A. galli* adults (*H. gallinarum* larvae); 90.3, 91.3, 92.7, 95.4, and 94.9% (*H. gallinarum* adults). In line with [17], a biochemical study conducted on the G3 and G4 groups, which were treated and infected, revealed a positive significant correlation at $P < 0.001$. When comparing the achieved to the G1 group, there was a noticeable increase in both ALT and AST, which was consistent with [18]. There is typically an increase in lactoperoxidase (LPO) in hymenolepiasis. The effectiveness of intestinal defense against oxidative stress brought on by parasite infection may also decline as a result of modifications in antioxidant enzyme activity and glutathione (GSH) levels in the gastrointestinal tract [19]. Thus, the pathophysiology linked to *H. nana* infection and the morphological alterations in the gastrointestinal system may be mostly caused by an imbalance between the oxidant and antioxidant activities of the infected mice [20]. The findings obtained by [21] were observed in G6, which was characterized by cellular infiltration, hydropic degeneration in the majority of hepatocytes, and crowded central and hepatic modes with totally hemolyzed red blood cells (RBCs). Cysticercoid migration via veins and lymphatics from the small intestine, together with a posterior spread from previously cysticercoids, is most likely the mechanism by which these organisms migrate to extra-intestinal locations.

Inflammatory cell buildup was found surrounding the bile duct, sinusoidal spaces, and the central and hepatic portal veins in the infected non-treated group's hepatic histological investigations. Certain hepatocytes have lost their nuclei, whereas the majority of them have the shape of a vacuole. These modifications may be attributed to the possible movement of some toxic metabolites from the gut to the liver [22]. Mebendazole (100 mg b.i.d. for 3 days) is a very insensitive treatment for fatal hymenolepiasis (*H. nana*), with response rates varying from only 18% to 40%, a finding we agree with [23]. We concur with the findings, which showed that in Afif, Saudi Arabia, *E. histolytica* (30.6%) was the most common intestinal parasite and a major public health concern. Coprolite samples from some of the cases that were submitted for analysis demonstrate the different methods by which this parasite can spread from animals to people [24]. The current study is in line with [25], who noted that any illnesses or infections that naturally spread from vertebrate animals to people are known as zoonosis. Over 200 different zoonosis are known to exist, and they account for a significant portion of human diseases, both old and new. Like rabies, certain zoonotic illnesses can

be completely prevented by immunization and other measures. The findings are consistent with [26], which states that most people have some sort of interaction with animals. Any illness or infection that can naturally spread from humans to other vertebrates or from animals to humans is known as a zoonotic disease. More than 60% of infections that affect humans have zoonotic origins. This includes a wide variety of pathogens, including as bacteria, viruses, fungus, protozoa, and parasites. Climate change, urbanization, animal migration and trade, travel and tourism, vector biology, and human influences are some of the elements that have significantly impacted the emergence, reemergence, distribution, and patterns of zoonosis. Through direct or indirect contact, these animals' illnesses may spread.

The spread can occur in public places including pet stores, hospitals, streets, and homes. Transmission also frequently happens when these birds and animals are taken to competitions and exhibitions [27, 28]. Animal bites or scratches are typically how humans get diseases like pasteurellosis and cat scratch illness [29]. A parasite that can spread from animals to humans is called a zoonotic parasite. Since humans are not the primary host, the zoonotic parasite will behave differently in humans. Human health issues caused by zoonotic parasites can range from relatively moderate to extremely significant [30]. According to [31], *Ascaridia galli* and cestodes clogged the intestinal lumen and caused several histological alterations in the intestinal mucosa. This investigation was conducted at the same time as that study. According to the findings, the chicken sector is seriously at risk from parasite co-infection. It was advised that to address such problems, stringent aseptic measure management techniques be used in conjunction with suitable therapy and prevention measures. Poor operational procedures and hygiene were found in the positive farms with high raspberry intensity, which could account for this frequency rate. The anatomized positive farms can harbor and propagate the parasite infection due to these techniques. According to [32], intestinal parasite infection (IPI) is a rising worldwide health concern. Our research supports this finding. The idea that some disorders are prevented because of medication, mindfulness juggernauts, and prevention efforts is still unproven in several parts of the world. IPI frequency rates in Saudi Arabia are high, according to recent studies; nevertheless, these rates differ amongst megacities and age groups within the country. Along with age, gender, health awareness, health behaviors, and socioeconomic position, the frequency of IPI has also been connected to several risk variables. Therefore, to cover and lessen the spread of parasite infections, particularly among young children, more attention should be paid to IPIs in Saudi Arabia and the difficult factors should be better handled. In contrast to pastoral communities (23.8), collaborative populations (76.2) may have higher infection rates [33, 34], which reported the same normal for this age group. Since the parasite rarely encysts in the intestinal lumen of beasts, which is a crucial feature in the parasite's transmission, we concur with [35] who claimed that *E. histolytica* isn't fluently transmitted from animals to humans. Once more, subclinical amebiasis in humans serves as the primary host for the sponger's transmission from human to human or between human and beast. Our research follows in the footsteps of [36], which found that intestinal protozoan infections of which *Giardia* and *Entamoeba* infections are the most common remain a public health concern in Yemen. According to a statistical study, contact with beasts and poor personal cleanliness were significant predictors of intestinal protozoan infections.

Alam et al.'s research [37] demonstrated that there was a significant difference in the likelihood of *E. histolytica* antigen positivity between all age groups among hounds from the immature age

group (6 months to 1 time) compared to hounds from the other two aged age groups. According to statistics, there was no discernible frequency difference between manish and womanish hounds. The highest frequency rate of *E. histolytica* antigens was found in the original hounds. The results show that there is a substantial positive trend between the different colored types of hounds. The imported types (11 of 115,9.5, 95 CI = 10.4) and crossbred types (19 of 239,8.3, 95 CI = ± 7.47) are the next in line. According to these results, hounds might be crucial to the spread of this infection. In the underdeveloped world, many zoonotic diseases are indigenous, which has a detrimental effect on the health and way of life of the impoverished. The current study is consistent with the designation of neglected zoonosis since, due to their aboriginal origin, they have been labeled as such and have been underreported and ignored by many supporting agencies in comparison to emerging and reemerging zoonosis [38]. The following are significant zoonotic illnesses: leishmaniasis, echinococcosis, brucellosis, anthrax, cysticercosis, rabies, and foodborne trematode infections [39, 40]. Neglected zoonosis, or diseases caused by animals that people have forgotten about, includes rabies in Africa and Asia, echinococcosis and taeniasis (*Taenia solium*) in Asia, Africa, and Latin America, leishmaniasis in Asia and Africa, cysticercosis, and foodborne trematodiasis in Africa [41]. Cooperation in research with [42], the health of humans and animals is greatly impacted by zoonosis. Although it is difficult to measure, factors including illness prevalence, incidence, morbidity, mortality, and economic loss can be used to gauge the impact of zoonosis. When comparing the mean diameter of hepatic granulomas in all treatment groups to the corresponding positive control group, Salama et al. [43] observed a statistically significant decrease. The combined group showed notable reductions as compared to other treated groups. There was no statistically significant difference between any drug-treated group during the acute phase of the illness and its comparable group during the chronic phase. The acute positive control group's liver sections showed several cellular granulomas made of a collection of inflammatory cells, such as lymphocytes, eosinophils, and macrophages. Excessive fibrous tissue and numerous fibrocellular granulomas were observed in the chronic positive control group. Cellular granulomas from acute Metformin (MTF) and acute ABZ were studied. Fibro-cellular granulomas made of inflammatory cells with sparse fibrous tissue were observed in chronic ABZ and chronic MTF cases. In the groups receiving combination treatment, granuloma clearance was noted. This study confirms the findings of [5], who found that ABZ increased serum AST levels (75.33; 11.40 UIL) compared to the control group's (35.33; 1.2 UIL). Additionally, when effective ABZ is used on ALT, the serum ALT level increases (62.36; 6.47 UIL) compared to the control group's (37-60; 2.70 UIL). The capacity of ABZ to create oxidative stress in chicken liver has been shown by the current results; histological data supporting the causes of liver damage and alteration in liver function also supported this conclusion.

5. Conclusions

The present study showed that intestinal examination recorded prevalent *Ascaris lumbricoides* with a percentage 70% in intestine of chickens of farm (Dawmat AlJandal) in Al-Jouf at a significant level. G2 recorded a percentage 48% in number of worms *Ascaris*, while G4 recorded a percentage 25%. Farm factors such as breed, clinical signs, and movement pose a great risk of farm (Dawmat AlJandal) to chickens breeding. Results revealed that *H. nana* and *E. histolytica* (30%) were the most prevalent intestinal parasites among the samples for analysis. We found the lowest percentage of

tapeworms in chickens of G4 (17.3%), while G2 recorded 41.6%. The number of worms in one sector ranged from 1-5, which are of the type *H. nana*. Infection with *Ascaris* and *H. nana* or *E. histolytica* are currently a serious worldwide public health problem with the most common occurrence in the pediatric population. It is therefore important to introduce targeted intervention. The measures to prevent the spread of these parasites require therapy for treatment (with repetition after 14 days of the first dose of antihelmintics), and should be considered by the owners of these pet birds, breeders, veterinarians, and public health organizations. The levels of AST in the plasma of groups (G3) and (G4) recorded a significant increase compared to the infected control group (G2) and control group (G1) at $P < 0.001$ and $P < 0.01$. Also The levels of ALT in the plasma of groups (G3) and (G4) recorded a significant increase compared to the infected control group (G2) at $P < 0.001$ and $P < 0.01$. The histological study of both the liver and intestines demonstrated the pathological effect of the tissues treated with ABZ, and on the contrary, the treatment affected the decrease in the number of worms in the intestines.

Supplementary Materials: All data are submitted in the text.

Author Contributions: **Conceptualization:** HTH and IA; **methodology:** HTH, AJ.T.A, FR.R., HS.M.S, IA; **software:** IA; **validation:** HTH and IA; **formal analysis:** HTH and IA; **investigation:** HTH, AJ.T.A, FR.R., HS.M.S, IA; **resources:** HTH, AJ.T.A, FR.R., HS.M.S, IA; **data curation:** HTH and IA; **writing-original draft preparation:** HTH and IA; **writing-review and editing:** HTH and IA; **supervision:** HTH; **project administration:** HTH and IA; **funding acquisition:** HTH and IA; **All authors have read and agreed to the published version of the manuscript.**

Ethical Consideration: This study was performed in line with the principles of the Declaration of Helsinki. As the protocol used in this study is conducted without modifications in accordance to a protocol which is published, well-established, and previously approved by Ethical Committee, no additional approval is needed.

Acknowledgments: We do acknowledge all colleagues who support and discuss the work to be in the present form.

Conflicts of Interest: The authors declare no conflict of interest.

References

1. Jeblawi, R. (2009). Study On Zoonoses And Preventive And Control Measures In The Arab World, Kafrelsheikh, Vet. Med. J., 3rd Sci. Congress, pp. (138-162).
2. Chai, J.Y., Jung, B.K., Hong, S.J. (2021). Albendazole and Mebendazole as Anti-Parasitic and Anti-Cancer Agents: an Update. Korean J. Parasitol. 59(3): 189-225. <https://doi.org/10.3347/kjp.2021.59.3.189>.
3. WHO (2019). A Tripartite Guide to Addressing Zoonotic Diseases in Countries Prevalence of Intestinal Parasites in animals, Saudi Arabia.
4. Allameh, A., Niayesh-Mehr, R., Aliarab, A., Sebastiani, G., Pantopoulos, K. (2023). Oxidative Stress in Liver Pathophysiology and Disease. Antioxidants (Basel). 12(9):1653. doi: 10.3390/antiox12091653.
5. EL-sheikh, S., Shams, G.E., Fouad, A.A. (2022). Effect of albendazole on liver and kidney function. Bulletin of Faculty of Science, Zagazig University (BFSZU). 2:22-28. DOI: 10.21608/bfszu.2022.109207.1110.

6. Zaefarian, F., Abdollahi, M.R., Aaron, C., Ravindran, V. (2019). Avian Liver: The Forgotten Organ, *Animals (Basel)*. 9(2):63. doi: 10.3390/ani9020063.
7. Poultry, D.V. (2024). Albendazole for Chickens and Ducks. <https://poultrydvm.com/drugs/albendazole>.
8. Pene, P., Mojon, M., Garin, J.P., Coulaud, J.P., Rossignol, J.F. (1982). Albendazole: a new broad spectrum anthelmintic Double-blind multicenter clinical trial. *Am J Trop Med Hyg*. 31:263-266. <https://doi.org/10.4269/ajtmh.1982.31.263>.
9. Chai, J.Y., Hong, S.T. (1985). Chemotherapy of intestinal nematode infections. *J Korean Soc Chemother*. 3:119-129. [[Google Scholar](#)].
10. Keiser, J., Utzinger, J. (2010). The drugs we have and the drugs we need against major helminth infections. *Adv Parasitol*. 73:197-230. doi: 10.1016/S0065-308X(10)73008-6. [[PubMed](#)] [[CrossRef](#)] [[Google Scholar](#)].
11. Moser, W., Schindler, C., Keiser, J. (2019). Drug combinations against soil-transmitted helminth infections. *Adv Parasitol*. 103:91-115. doi: 10.1016/bs.apar.2018.08.002. [[PubMed](#)] [[CrossRef](#)] [[Google Scholar](#)].
12. Soukhathammavong, P.A., Sayasone, S., Phongluxa, K., Xayaseng, V., Utzinger, J., Vounatsou, P., Hatz, C., Akkhavong, K., Keiser, J., Odermatt, P. (2012). Low efficacy of single-dose albendazole and mebendazole against hookworm and effect on concomitant helminth infection in Lao PDR. *PLoS Negl Trop Dis*. 6:e1417. doi: 10.1371/journal.pntd.0001417. [[PMC free article](#)] [[PubMed](#)] [[CrossRef](#)] [[Google Scholar](#)].
13. Chai, J.Y., Hong, S.T., Sohn, W.M., Lee, S.H. (1986). Anthelmintic effect of albendazole (Alzental®) on human intestinal nematodes. *J Korean Soc Chemother*. 4:86-88. (in Korean) [[Google Scholar](#)].
14. Culling, G. (1957). *Handbook of histopathological techniques*. 1st edn. Butterworth. Co. Ltd., London (chapter 4. Technique).
15. Issa, R.M. (2007). *Schistosoma mansoni*: The prophylactic and curative effects of propolis in experimentally infected mice. *Rawal. Med. J*. 6:e1417.
16. Tucker, T.A., Yazwinski, L., Reynolds, Z. (2007). Determination of the Anthelmintic Efficacy of Albendazole in the Treatment of Chickens Naturally Infected with Gastrointestinal Helminths. *The Journal of Applied Poultry Research* 16(3):392-396. DOI:10.1093/japr/16.3.392.
17. Goswami, R., Singh, S., Kataria, M., Somvarshi, R. (2011). Clinicopathological studies on spontaneous *Hymenolepis diminuta* infection in wild and laboratory rats. *Braz J Vet Pathol*. 4(2):103-111.
18. El-Naggar, S. (2011). Lack of the beneficial effects of Mirazid (*Commiphora molmol*) when administered with chemotherapeutic agents on Ehrlich ascetic carcinoma bearing mice. *Adv Biol. Res*. 5(4):193-199.
19. Farhadi, A., Banan, A., Fields, J., Keshavarzian, A. (2003). Intestinal barrier: an interface between health and disease. *J. Gastroent. Hepat*. 18:479-497.
20. Kosik-Bogacka, D.I., Baranowska-Bosiacka, I., Nocoń, I., Jakubowska, K., Chlubek, D. (2011). *Hymenolepis diminuta*: Activity of antioxidant enzymes in different parts of rat gastrointestinal tract. *Exper. Parasitol.*, 128(3): 265-271.

21. Ismail, H., Hamouda, H., Baalash, A., Haibs, A., Ismail, G., Shamloula, M. (2007). Immunohistochemical and neurotransmitter changes in the brain of mice infected with *Hymenolepis nana*. *Tanta Med Sci J.* 2(1):117-132. [[Google Scholar](#)].
22. Parvathi, J., Karemungikar, A. (2011). Leucocyte variation, an insight of host defenses during hymenolepiasis and restoration with praziquantel. *Indian J. Pharm. Sci.* 73(1): 76-79.
23. Keystone, J.S., Murdocch, J.K. (1979). Mebendazole. *Ann Intern Med.* 9.
24. Charlie, P., Abu Bakr, S.A., Alcantara, J.C., Aziz, A., Alotaibi, A., Alabdan, M.A. (2015). Prevalence of Intestinal Parasites in Afif, Saudi Arabia: A 5-year Restrospective Study. *Int.J.Curr.Microbiol.App.Sci.* 4(5): 24-34, <http://www.ijcmas.com>.
25. WHO, Bond, J., Pio, A., (2020). Zoonotic parasitic disease. 2020.
26. Rahman, T., Abdus Sobur, M., Saiful Islam, M., Ievy, S., Hossain, J., El Zowalaty, M., Rahman, A., Ashour, H. (2020). Zoonotic Diseases: Etiology, Impact, and Control, *Microorganisms.* 8(9):1405. doi: 10.3390/microorganisms8091405.
27. Belchior, E., Barataud, D., Ollivier, R., Capek, I., Laroucau, K., De Barbeyrac, B., Hubert, B. (2011). Psittacosis outbreak after participation in a bird fair, Western France, December 2008. *Epidemiol. Infect.* 139:1637-1641. [[Google Scholar](#)] [[CrossRef](#)].
28. Vanrompay, D., Harkinezhad, T., Van de Walle, M., Beeckman, D., Van Droogenbroeck, C., Verminnen, K., Leten, R., Martel, A., Cauwerts, K. (2007). *Chlamydophila psittaci* transmission from pet birds to humans. *Emerg. Infect. Dis.* 13:1108-1110. [[Google Scholar](#)] [[CrossRef](#)].
29. ChomeI, B.B. (2014). Emerging and Re-Emerging Zoonoses of Dogs and Cats. *Animals* 4:434-445. [[Google Scholar](#)] [[CrossRef](#)].
30. Stan Blackwell, D.V.M. (2015). Zoonotic Parasites, TVMA Member, Nacogdoches, TX. Published December 2015. <https://www.texvetpets.org/article/zoonotic-parasites/>.
31. Mousa, M.R., Attia, M.M., Salem, H.M., Al-Hoshani, N., Thabit, H, Ibrahim, M.A., Albohiri, H.H., Khan, S.A., El-Saadony, M.T., El-Tarabily, K.A., El-Saied, M.A. (2024). Co-infection of the gut with protozoal and metazoal parasites in broiler and laying chickens. *Poult Sci.* 103(1):103227. doi: 10.1016/j.psj.2023.103227.
32. Al-Malki, J.S. (2021). Prevalence and risk factors of parasitic diseases among Saudi children. *Saudi Medical Journal* 42(6):612-619. DOI: <https://doi.org/10.15537/smj.2021.42.6.20200784>.
33. Hawash, Y.A., Dorgham, L.S., Amir, E.A.M. (2015). Prevalence of intestinal protozoa among Saudi patients with chronic renal failure: a case-control study. *J Trop Med.* 2015:563478.
34. Gebretsadik, D., Metaferia, Y., Seid, A., Fenta, G.M., Gedefie, A. (2018). Prevalence of intestinal parasitic infection among children under 5 years of age at Dessie Referral Hospital: cross sectional study. *BMC Res Notes* 11: 771.
35. Junaidi, J., Cahyaningsih, U., Purnawarman, T., Latif, H., Sudarnika, E., Hayati, z., Muslina, M. (2020). *Entamoeba histolytica* Neglected Tropical Diseases (NTDs) Agents that Infect Humans and Some Other Mammals: A Review, E3S Web of Conferences 151, 1st ICVAES 201901019 <https://doi.org/10.1051/e3sconf/202015101019>.
36. Alyousefi, N.A., Mahdy, M., Mahmud, R., Lim, Y. (2011). Factors Associated with High Prevalence of Intestinal Protozoan Infections among Patients in Sana'a City, Yemen. <https://journals.plos.org/plosone/article?id=10.1371/journal.pone.0022044>.

37. Alam, M., Maqbool, A., Nazir, M., Lateef, M., Khan, M., Lindsay, D. (2014). *Entamoeba* infections in different populations of dogs in an endemic area of Lahore, Pakistan, *Vet Parasitol.* 207(3-4):216-9. doi: 0.1016/j.vetpar.2014.12.001. Epub 2014 Dec 11.
38. Maudlin, I., Eisler, M.C., Welburn, S.C. (2009). Neglected and endemic zoonoses. *Philos. Trans. R. SocLond. B. Biol. Sci.* 364: 2777-2787. [[Google Scholar](#)] [[CrossRef](#)].
39. Mrzljak, A., Novak, R., Pandak, N., Tabain, I., Franusic, L., Barbic, L., Bogdanic, M., Savic, V., Mikulic, D., Pavicic-Saric, J., et al. (2020). Emerging and neglected zoonoses in transplant population. *World J. Transplant.* 10:47-63. [[Google Scholar](#)] [[CrossRef](#)].
40. Elelu, N., Aiyedun, J.O., Mohammed, I.G., Oludairo, O.O., Odetokun, I.A., Mohammed, K.M., Bale, J.O., Nuru, S. (2019). Neglected zoonotic diseases in Nigeria: Role of the public health veterinarian. *Pan Afr. Med. J.* 32:36. [[Google Scholar](#)] [[CrossRef](#)].
41. WHO, Bond, J., Pio, A. (2020). Zoonotic parasitic disease, 2020.
42. Meslin, F.X. (2006). Impact of zoonoses on human health. *Vet. Ital.* 42:369-379. [[Google Scholar](#)].
43. Salama, A.M., Elmahy R.A., Ibrahim H.A., Amer, A.I.M., Eltantawy, A.F., Dina I., Elgendy, D.I. (2023). Effects of metformin on parasitological, pathological changes in the brain and liver and immunological aspects during visceral toxocariasis in mice. *Parasitology Research* 122:3213-3231. <https://doi.org/10.1007/s00436-023-08011-1>.